Saoji *et al.*
Egyptian Pediatric Association Gazette (2024) 72:8
https://doi.org/10.1186/s43054-024-00252-8

Egyptian Pediatric
Association Gazette

CASE REPORT Open Access

An atypical presentation of ulcerative colitis: case report

Avanti Saoji[1], Madhura Kavishwar[1], Praveen Unki[1*] and Surbhi Rathi[1]

Abstract

Background Bloody diarrhea in children often indicates a severe gastrointestinal illness. Although infections are the most likely cause, inflammatory bowel disease (IBD) is a close mimic. IBD generally presents with chronic and persistent symptoms requiring long-term treatment. Hence, acute or atypical presentations may mislead the physician leading to delays in diagnosis. We report the case of an atypical presentation of ulcerative colitis.

Case presentation We present the case of a 6-year-old girl with acute symptoms of bloody diarrhea, fever, abdominal pain, and tenesmus for 5 days. The child came to us after the non-resolution of symptoms after treatment from a local practitioner. The child was found to have signs of chronic malnutrition and clubbing on general examination. After ruling out infective causes, the child was evaluated further by colonoscopy, which revealed lesions suggestive of ulcerative colitis, and hence started on topical and oral treatment for the same.

Conclusion Awareness about the disease and its atypical presentations like poor growth, anemia, or extraintestinal manifestations is necessary, especially in primary healthcare and resource-poor settings as it can lead to early diagnosis, referral, and treatment initiation.

Keywords Inflammatory bowel disease, Ulcerative colitis, Blood in stool, Chronic malnutrition, Case report

Background

Inflammatory bowel disease (IBD) comprises two chronic gastrointestinal (GI) inflammatory diseases—ulcerative colitis (UC) and Crohn's disease (CD). They present with chronic and persistent GI symptoms and require long-term treatment and monitoring. Acute symptoms or atypical presentations may lead to delays in diagnosis. It may further lead to the affection of growth and development, bone health, and psychosocial functioning in children and adolescents and contribute to significant morbidity and mortality [1]. It also poses a significant load on the healthcare system [2]. Hence, awareness about the disease and its varied manifestations can aid in early detection and early initiation of treatment to improve outcomes. We report the case of one such atypical presentation of ulcerative colitis.

Case presentation

We present the case of a 6-year-old girl who came to our tertiary care center with acute bloody diarrhea for a duration of 5 days associated with fever, abdominal pain, and tenesmus. Her stools were non-foul-smelling, large in quantity, and had fresh blood (about 3–5 ml in each stool), associated with pain in the abdomen just prior to passage. The child had no similar complaints previously and no significant past medical or surgical history. For the above complaints, the child was started on antibiotics at a local hospital and was transfused with packed cells in view of severe anemia.

The child visited our hospital due to the non-resolution of symptoms despite treatment. Physical appearance revealed a pale, malnourished, and stunted girl. Anthropometry revealed weight and height for age less than the

*Correspondence:
Praveen Unki
praveenu3@gmail.com
[1] Department of Pediatrics, TNMC and BYL Nair Charitable Hospital, Mumbai 400008, India

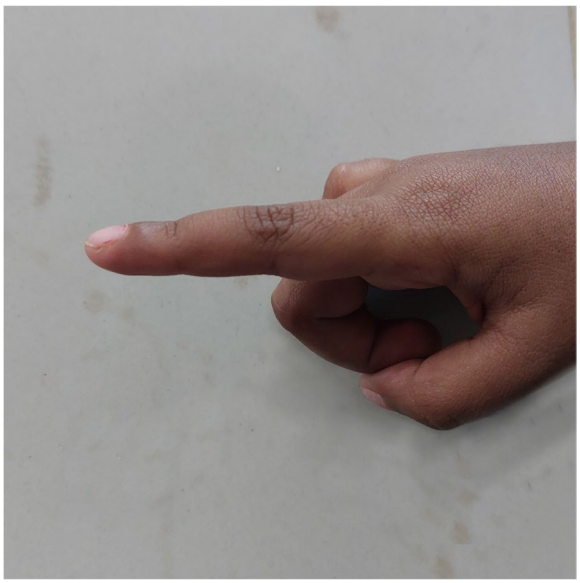

Fig. 1 Grade III clubbing seen in our case of ulcerative colitis

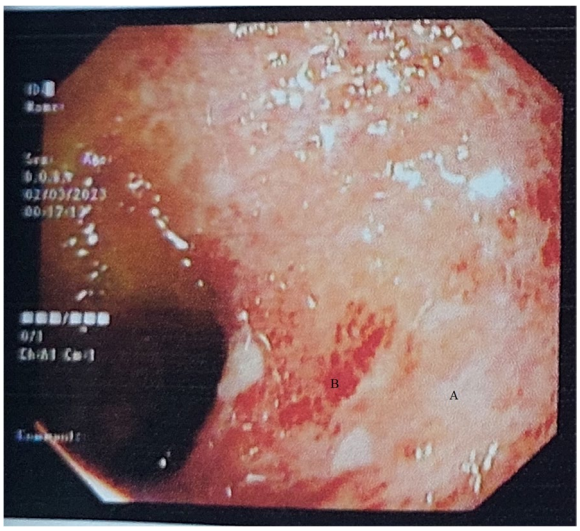

Fig. 2 Colonoscopy images of the patient showing **A** edematous and erythematous mucosa of the colon and **B** superficial ulcerations and bleeding

3rd centile with a BMI of 11.5 kg/m^2, thus suggesting a chronic cause for her malnutrition. On further evaluation, the child was noticed to have clubbing (as shown in Fig. 1) and cheilosis. No cyanosis, icterus, or lymphadenopathy was seen. The local perianal examination had no obvious abnormality. The abdomen was soft and nontender, and the liver was palpable 3 cm below the right costal margin. Other systems were within normal limits.

On investigations, a complete blood count revealed a hemoglobin of 8.4 g/dl, platelets of 77,000/mm^3, and total counts of 15,000/mm^3. Stool examination was positive for RBCs but, however, revealed no organisms or pus cells ruling out infective causes. Further testing was done to evaluate for etiology of chronic disease in the child. Liver functions, renal functions, and coagulation profile were within normal limits. C-reactive protein and erythrocyte sedimentation rates were normal. Tuberculosis and HIV were ruled out. Chest X-ray revealed no abnormal findings. 2D echo was within normal limits. Ultrasonography of the abdomen was suggestive of a thickened rectum, sigmoid colon, and part of the descending colon. Fetal calprotectin levels were inconclusive. Colonoscopy was planned, and it revealed diffuse inflammatory lesions from the rectum to the ascending colon sparing the terminal ileum and cecum as shown in Fig. 2. Biopsy from the sites was suggestive of superficial ulcerations, lymphoplasmacytic infiltrates in lamina propria, cryptitis, and crypt abscess in the colon suggestive of ulcerative colitis. Hence, she was started on 5-aminosalicylic acid (Mesalamine) orally and topically in the form of an enema. Multivitamins and mineral supplements were also added, and parents were counseled about an appropriate diet. The child followed up after 2 weeks of discharge. There were no repeat episodes of bleeding. The child had resumed school and was active, and there was a weight gain of 1 kg.

Discussion

Inflammatory bowel disease constitutes chronic inflammatory disorders of the gastrointestinal tract [1]. These occur due to a complex interplay of various factors like genetic, environmental, microbial, and adaptive immunity of the host and result in a dysregulated mucosal immune response against the commensal intestinal microbiota [3]. Although most commonly seen during adolescence and young adulthood, an increasing number of children are now being diagnosed even at a younger age with early-onset (0–5 years) and very early-onset (VEO) diseases (0–2 years) [4, 5].

The diagnosis of IBD is generally entertained in children with chronic or persistent symptoms like abdominal pain, diarrhea, rectal bleeding, and weight loss. Bloody diarrhea is the most common presenting complaint in UC whereas CD may present with vague abdominal pain, diarrhea, or chronic symptoms such as unexplained anemia, fever, weight loss, or growth retardation. The classic "triad" of abdominal pain, diarrhea, and weight loss occurs in only 25% of patients with CD [6]. Extraintestinal manifestations may involve nearly any organ system—but common ones include the musculoskeletal, dermatologic, hepato-pancreato-biliary, ocular, renal, and hematological systems [7]. These may present at

diagnosis in 6 to 23% of children with a higher frequency in those > 6 years [8, 9].

It is important to exclude enteric infections before making a diagnosis of IBD. The primary findings that differentiate infection from IBD are positive stool cultures and duration of diarrhea in these patients. Those who have no identified pathogen and/or symptoms with a duration of > 2 weeks are likely to have IBD [10]. Murphy [11] suggests that although GI infections may be the most likely cause of bloody diarrhea in children, the possibility of inflammatory bowel disease should always be kept in mind especially if associated with signs like impaired growth, clubbing, oral or perioral abnormalities. Impairment of growth in children may precede the intestinal mucosal lesion by months to years [12, 13]. This is similar to what we observed in our case.

The classification of IBD is complex and characterized by some rare phenotypes that may be atypical or unusual. The recognition of the typical features of CD and UC, identification of atypical phenotypes that are still consistent with a diagnosis of CD or UC, and knowledge of those factors that preclude a diagnosis of one or the other are vital for diagnosis. Thus, a diagnosis of IBD should be supported on the basis of history, physical examination, laboratory investigations, histopathology, and imaging of the small bowel.

The revised Porto criteria accepted by the European Society for Paediatric Gastroenterology Hepatology and Nutrition (ESPGHAN) are a novel evidence-based approach to the definition of IBD [14]. It has a methodological approach and incorporates the Paris phenotypic classification of PIBD [15]. It also helps in the delineation of atypical phenotypes of IBD. Thus, it enables clinicians to properly diagnose each individual subtype. The criteria also consider advanced diagnostic imaging modalities like capsule endoscopy, along with serological and fecal biomarkers for diagnosis.

Reliable features to diagnose ulcerative colitis include continuous mucosal inflammation of the colon, starting from the rectum, without small bowel involvement and without granulomas on biopsy [8, 10, 16]. The typical macroscopic features seen are erythema, granularity, friability, purulent exudates, and ulcers that generally appear as superficial small ulcers. However, certain atypical phenotypes like macroscopic rectal sparing, isolated upper GI involvement in the form of non-serpiginous gastric ulcers, normal crypt architecture, absence of chronicity in biopsies, or a cecal patch may also be seen [14]. The results of the colonoscopy seen in our case match with the above findings.

Crohn's disease typically manifests primarily in the ileum or colon, although any part of the GIT may be affected. CD may also present with extraintestinal manifestations initially. Key features of CD include the presence of skip lesions, non-contiguous serpentine and linear ulcerations, cobblestoning, stenosis/stricturing of the bowel, thickening of the bowel wall, or inflamed ileum with a normal cecum, with histological presence of well-formed non-caseating granulomas [14].

IBD type unclassified (IBD-U) is a term referring to patients with definite IBD, wherein the inflammation is limited to the colon and the differentiation between UC and CD remains uncertain even after a complete workup [14].

Fecal markers like calprotectin or lactoferrin are very sensitive in the detection of mucosal inflammation but are not very specific for IBD. Certain serological markers of IBD like anti-*Saccharomyces cerevisiae* antibody (ASCA) or perinuclear anti-neutrophil cytoplasmic antibodies (pANCA) may suggest an increased likelihood for IBD in atypical cases and may also help to differentiate CD from UC in cases of IBD-U [14].

An increasing number of cases of pediatric IBD are now being reported in India [17] which could be due to increasing awareness, improved diagnostic techniques, and enhanced access to specialized healthcare systems. However, atypical presentations and unique age-related issues of children make diagnoses of pediatric IBD challenging [18–20].

The treatment for IBD requires long-term care, follow-up, and support. The goals of treatment include the elimination of symptoms and restoring quality of life, restoring normal growth, and prevention of complications. Medical therapy includes drugs needed to induce remissions like aminosalicylates and corticosteroids; immunomodulators like azathioprine, methotrexate, and 6-mercaptompurine; and newer biologicals like monoclonal antibodies such as infliximab, adalimumab, and vedolizumab which are helpful in remission as well as maintenance and thus can heal the mucosa and augment growth [1].

Surgical intervention may be required in select cases like intractable disease and fulminant disease unresponsive to medical management. Psychosocial support for the child and family is also of utmost importance for adherence to treatment.

Conclusion

IBD is increasingly being reported in India. Knowledge about the disease and its atypical presentations in the form of poor growth, anemia, or extraintestinal manifestations is necessary, especially in primary healthcare and resource-poor settings to aid in early diagnosis, referral, and initiation of treatment.

Acknowledgements
None.

Authors' contributions
AS: data curation, editing, writing—original draft preparation, and investigation. MK: data curation and investigation. PU: conceptualization, investigation, supervision, reviewing, and editing. SR: supervision and reviewing.

Funding
None.

Availability of data and materials
Not applicable.

Declarations

Ethics approval and consent to participate
Not applicable.

Consent for publication
Written informed consent from the child's parent for publication was obtained.

Competing interests
The authors declare that they have no competing interests.

Received: 18 September 2023 Accepted: 29 December 2023
Published online: 14 February 2024

References

1. Rosen MJ, Dhawan A, Saeed SA (2015) Inflammatory bowel disease in children and adolescents. JAMA Pediatr 169(11):1053
2. Jain M, Venkataraman J (2021) Inflammatory bowel disease: an Indian perspective. Indian J Med Res 153(4):421
3. Khor B, Gardet A, Xavier RJ (2011) Genetics and pathogenesis of inflammatory bowel disease. Nature 474(7351):307
4. Maisawa S, Sasaki M, Ida S, Uchida K, Kagimoto S, Shimizu T et al (2013) Characteristics of inflammatory bowel disease with an onset before eight years of age: a multicenter epidemiological survey in Japan. J Gastroenterol Hepatol 28(3):499–504
5. Aloi M, Lionetti P, Barabino A, Guariso G, Costa S, Fontana M et al (2014) Phenotype and disease course of early-onset pediatric inflammatory bowel disease. Inflamm Bowel Dis 20(4):597–605
6. Sawczenko A, Sandhu BK (2003) Presenting features of inflammatory bowel disease in Great Britain and Ireland. Arch Dis Child 88:995–1000
7. Luzoro A, Sabat P, Guzmán L, Frias F (2011) Extraintestinal manifestations of inflammatory bowel disease. Gastroenterol Hepatol (N Y) 7(4):235
8. Vernier-Massouille G, Balde M, Salleron J, Turck D, Dupas JL, Mouterde O et al (2008) Natural history of pediatric Crohn's disease: a population-based cohort study. Gastroenterology 135(4):1106–1113
9. Jose FA, Garnett EA, Vittinghoff E, Ferry GD, Winter HS, Baldassana RN et al (2009) Development of extraintestinal manifestations in pediatric patients with inflammatory bowel disease. Inflamm Bowel Dis 15(1):63–68
10. Murphy MS (2008) Management of bloody diarrhoea in children in primary care. BMJ 336(7651):1010–1015
11 Sokic-Milutinovic A, Pavlovic-Markovic A, Tomasevic RS, Lukic S (2022) Diarrhea as a clinical challenge: general practitioner approach. Dig Dis 20:282–9. S. Karger AG
12. Kapoor A, Bhatia V, Sibal A (2016) Pediatric inflammatory bowel disease. Indian Pediatr 53(11):993–1002
13. Levine A, Koletzko S, Turner D, Escher JC, Cucchiara S, De Ridder L et al (2014) ESPGHAN revised Porto criteria for the diagnosis of inflammatory bowel disease in children and adolescents. J Pediatr Gastroenterol Nutr 58(6):795–806
14. Levine A, Griffiths A, Markowitz J, Wilson DC, Turner D, Russell RK et al (2011) Pediatric modification of the Montreal classification for inflammatory bowel disease: the Paris classification. Inflamm Bowel Dis 17(6):1314–1321
15. Van Limbergen J, Russell RK, Drummond HE, Aldhous MC, Round NK, Nimmo ER et al (2008) Definition of phenotypic characteristics of childhood-onset inflammatory bowel disease. Gastroenterology 135(4):1114–1122
16. Bousvaros A, Antonioli DA, Colletti RB, Dubinsky MC, Glickman JN, Gold BD et al (2007) Differentiating ulcerative colitis from Crohn disease in children and young adults: report of a working group of the North American Society for Pediatric Gastroenterology, Hepatology, and Nutrition and the Crohn's and Colitis Foundation of America. J Pediatr Gastroenterol Nutr 44(5):653–674. https://doi.org/10.1097/MPG.0b013e31805563f3
17. Philip M, Augustine P, Thomas V, Ramesh GN, Vinayakumar KR, Ramachandran TM et al (2017) Multi-center prospective survey of inflammatory bowel diseases in Kerala: more than 2000 cases. Indian J Gastroenterol 36(6):459–467
18. Sidiropoulos M, Skuy B (2011) Crohn's disease presenting with atypical mucocutaneous lesions in an 11 year old boy. Mcgill J Med 13(1):28
19. Cuffari C (2009) Diagnostic considerations in pediatric inflammatory bowel disease management. Gastroenterol Hepatol (N Y) 5(11):775–783
20. Shentova-Eneva R, Yankov I (2022) Pediatric Ulcerative Colitis. In: Pal P, editor. Ulcerative Colitis - Etiology, Diagnosis, Diet, Special Populations, and the Role of Interventional Endoscopy. IntechOpen, London. Available from: https://doi.org/10.5772/intechopen.102226

Publisher's Note