Habib *et al.*
Egyptian Pediatric Association Gazette (2023) 71:90
https://doi.org/10.1186/s43054-023-00235-1

Egyptian Pediatric Association Gazette

CASE REPORT

Open Access

SARS-CoV-2 induced urinary tract infection in an infant: a rare case

Murad Habib[1*], Mansoor Ahmed[1], Rafi Raza[1], Sibghatullah Babar[1] and Muhammad Amjad Chaudhary[1]

Abstract

Background The incidence of SARS-CoV-2 infection in pediatric population is less than 7% that too when associated with a urinary tract infection, the presentation is very rare. There have been numerous case reports in adults and adolescent population but very few in pediatrics and none in our socioeconomic.

Case presentation We present here the case of a 1-year-old boy with SARS-CoV-2 induced urinary tract infection whose urine biochemistry showed severe urinary tract infection but no hematuria. His COVID-PCR was positive. His chest radiograph showed bilateral lung infiltrates with peri-hilar lymphadenopathy. His computerized tomography scan showed infiltrates with lung fibrosis. He was admitted to the isolation ward, successfully managed, and discharged home after 5 days of in-hospital treatment.

Conclusion Pediatricians and pediatric emergency physicians should be vigilant and well aware of the atypical presentation of SARS-CoV-2 infection in infants and children, as they can present with both gastrointestinal and renal manifestations. And once missed, the patient may end up with devastating complications.

Keywords Children, SARS-CoV-2, Urinary tract infection

Background

The COVID-19 pandemic continues to impose a formidable morbidity and mortality toll on almost every country in the world. As the pandemic progresses into its sixth wave in Pakistan, new cases of infection have been identified and mounting evidence shows that protective immunity and peculiarity to the first one, and that phenomenon may explain the potential resurgence of cases. At present, Pakistan has reported 1,540,952 cases and 30,413 deaths from COVID-19 [1]. Daily infection rate surged to 872 cases, and this recent spike in COVID-19 cases across the country may turn into the sixth wave of the pandemic in Pakistan. Daily testing capacity is at 40,000 whereas total people inoculated with vaccine are 127,590,195 in a population of 220 million [1]. Pediatric population constitutes 12–14% of all confirmed cases of which 2.5–4% required hospitalization [2]. Although the SARS-CoV-2 predominately affects the respiratory system, it is important to emphasize the multi-organ involvement, including gastrointestinal system, nervous system, cardiovascular system, and urinary system. A patient's infectivity is determined by the presence of the virus in the body fluids, secretions, and excreta [3]. The persistence and clearance of viral RNA from different specimens of the patients with 2019 novel coronavirus disease (COVID-19) remain unclear. However, in both human and animal studies, limited persistence of SARS-CoV-2 in urine has been detected [4]. To date, there have been no studies published on the effect of SARS-CoV-2 infection on the lower urinary tract function in our socioeconomic. SARS-CoV-2 is soon to become an endemic just like other virus illnesses and will be seen by the primary health physicians. Thus, we present here a case of SARS-CoV-2 associated urinary tract infection who initially presented to a general physician with extra

*Correspondence:
Murad Habib
muradhabib007@gmail.com
[1] Department of Paediatric Surgery, The Children's Hospital, Pakistan Institute of Medical Sciences, Islamabad, Pakistan

pulmonary manifestations and later on to the hospital in sick condition.

Case presentation

We report here the a case of a 1-year-old patient who presented to the emergency with complaints of high-grade fever, difficulty passing urine, and loose stools. He was being treated at the local clinic for a urinary tract infection. He took the oral antibiotics but showed no response. On the contrary, fever showed an increasing pattern. He presented to the emergency department in sick condition and was cyanosed. The patient had to be resuscitated. At the time of presentation, his vitals were pulse 140 bpm, temperature 102 F, SpO2 91% at room temperature.

He was kept in isolation as a suspected case of SARS-CoV-2, as the child was oxygen dependent. His hematological workup revealed hemoglobin 10.5 g/dL, total leukocyte count 20 cells/μL, and platelets 450 cells/μL. His urine biochemistry showed white blood cells 20 per high-power field, red blood cells 3 per high-power field, and epithelial cells 2 per high-power field. His renal function tests were urea 32 mg/dL and creatinine 1.1 mg/dL. We are limited by the technology in our country so we could not isolate any viral pathogen. On the second day of the admission, his condition deteriorated further as his fever spiked to 104 F with cough and saturation dropped to SpO2 88% at room temperature. On auscultation, he had bilateral crepitation. His hematological workup showed an increased total leukocyte count of 23 cells/μL with predominant neutrophils of 78%. His C reactive protein was positive, fibrin degradation products were positive, D Dimers 502 ng/ml, and serum ferritin was 188 ng/ml. His chest radiograph showed bilateral lung infiltrates with peri-hilar lymphadenopathy (Fig. 1). His computerized tomography scan showed infiltrates with lung fibrosis (Fig. 2). He was admitted to the isolation ward. He was kept on broad-spectrum antibiotics including macrolides, fluoroquinolones, corticosteroids, anticoagulants, and vitamin supplemention. The patient showed remarkable improvement after 5 days of in-hospital treatment. His fever subsided and inflammatory markers were down. His SARS-CoV-2 PCR was repeated which came out to be negative. The patient was discharged on oral medication and was called for follow up.

Fig. 1 Chest X-ray shows bilateral hilar lymphadenopathy

Discussion

The diagnostic criteria for urinary tract infection is the presence of white blood cells, epithelial cells, red blood cells (hematuria), or all on urine biochemistry. A group of nephrologists at North well studied the association of acute kidney injury with SARS-CoV-2. They found out that 40% of the population presented with either WBCs or RBCs (hematuria) on urine analysis [5]. There is ample literature reporting adult SARS-CoV-2 infections, including the atypical ones compared to children, probably because pediatric patients are less commonly diagnosed due to lesser severity and mortality [4, 6]. We report here a similar case of COVID-19 with urinary tract infection in a pediatric patient. The patient took prior medication from a local clinic for urinary tract infection but failed to respond. On the contrary, the fever showed an increasing pattern. He presented to the emergency department in sick condition and was cyanosed with SpO2 91%. The patient had to be resuscitated. According to the World Health Organization (WHO), a patient presenting with fever, cough, and shortness of breath can be labeled as a case of suspected SARS-CoV-2 [3]. The patient having diarrhea is also not an uncommon presentation [1]. But there are no studies on SARS-CoV-2 and its association with the urinary tract [7].

Marand et al. reported the presence of WBCs and RBCs on urine analysis in SARS-CoV-2-positive patients which was associated with an increased mortality [8]. Almeida et al. reports the case of a 10-year-old female patient with hematuria, who was diagnosed with SARS-CoV-2 infection but with milder symptoms [9]. Our patient had leukocytosis (20 PHF), with predominant neutrophils. This might indicate the SARS-CoV-2-induced superimposed infection [10]. Hematuria and renal injury have been commonly described in viral respiratory tract infections including influenza A and B, adenovirus, and other pathogens.

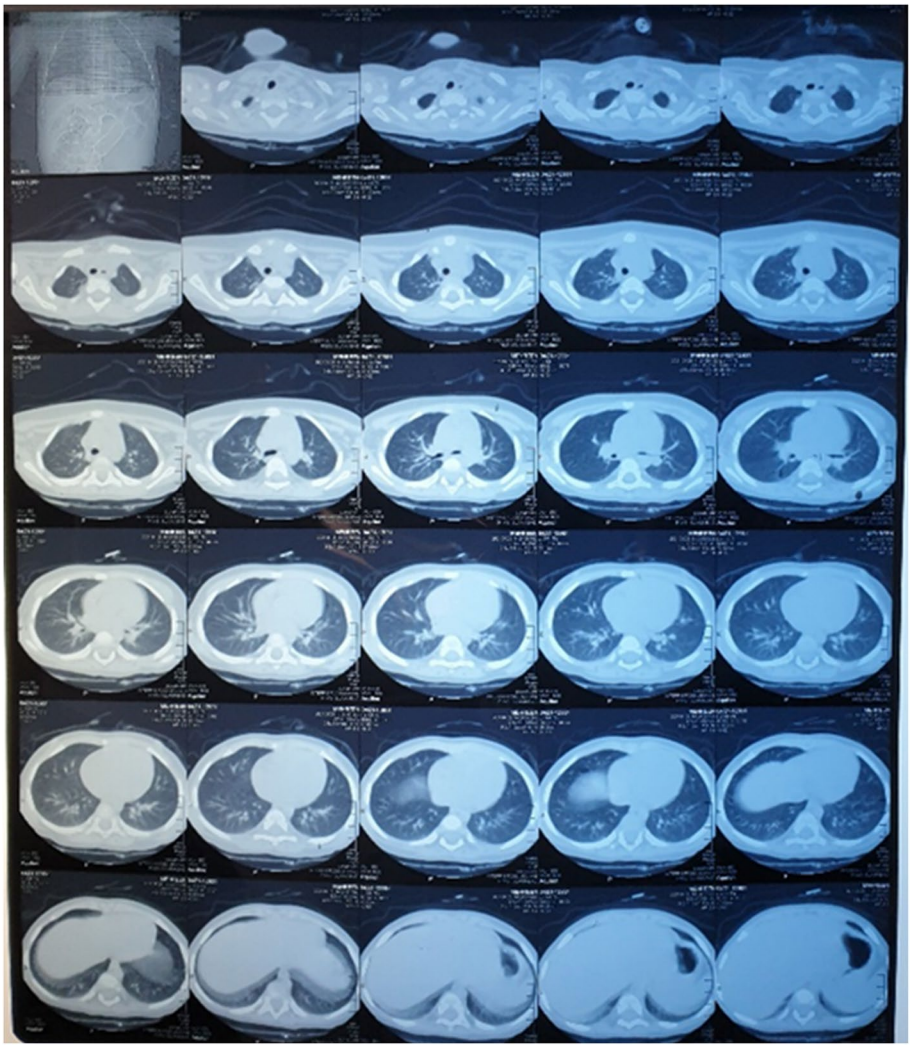

Fig. 2 CT-scan shows lung fibrosis

Kidney injury in adults hospitalized with COVID-19 infection appears to be a frequent finding, with a wide range of manifestations, from mild hematuria to severe renal failure. The pathogenesis of the renal injury is probably multi-factorial, as SARS-CoV-2 carries the spike protein (s protein) on its surface, binds to ACE2 receptor on the cell surface, and gets internalized. ACE2 is present in the alveolar epithelial cells, lining of the intestine, endothelial cells of both arteries and veins, and also arterial smooth muscle cells of various organs, including the direct cytopathic effects of the virus [11]. It also causes immune-complex mediated damage, as well as indirect effects on renal tissue, such as hypoxia, shock, and rhabdomyolysis and damage to urothelial cells hence resulting in hematuria and urinary tract infection (Fig. 3) [12].

The prevalence of renal manifestations is found to be 13.9%. Data from the adult population showed the prevalence of acute kidney injury in about half of the hospitalized patients with laboratory-confirmed COVID-19 infection, of whom 25% required ICU admission and 1/5 required dialysis with mortality as high as 50% [13]. The emergence of new variants like B.1.1.7, the 501Y.V2 has played a vital role in the spread of the disease with atypical symptoms as they are mutated to a newer and deadly form [3]. Therefore, it is paramount to identify such new variants and identify their pathophysiology as soon as possible in order to control the spread of infection further. It is also necessary to have a well-organized diagnostic criterion for atypical presentation of SARS-CoV-2; as false-negative tests might lead the patients to relax their adherence to health protocols. Improved

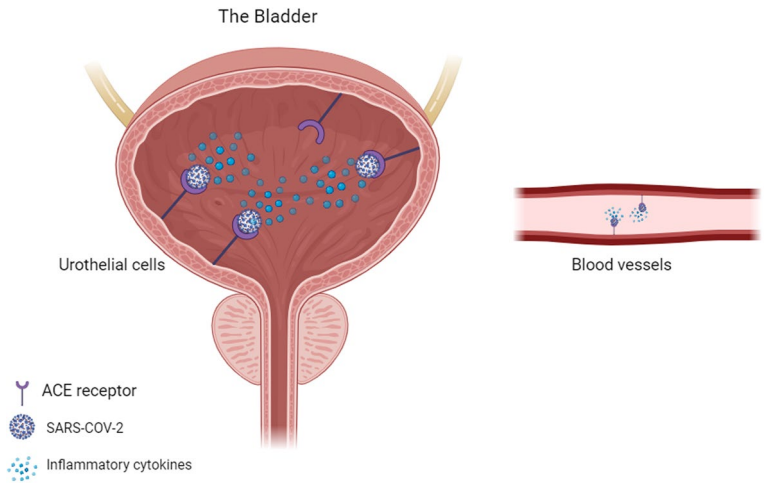

Fig. 3 Mechanism of SARS-CoV-2 associated bladder injury

RT-PCR tests for urine can isolate the pathogen from the urinary tract. But serological tests should be mandatory in order to overcome the false negatives. It is also a timely requirement to arrange a particular program including risk-stratified protocols for patients suspected of having COVID-19 who present with atypical symptoms [14].

Conclusion

Pediatricians and pediatric emergency physicians should be vigilant and well aware of the atypical presentation of SARS-CoV-2 infection in infants and children, as they can present with both gastrointestinal and renal manifestations. And once missed, the patient may end up with devastating complications.

Acknowledgements
None.

Authors' contributions
Concept of study: MH, SB. Acquisition of data: MA, RR. Writing, drafting: MH, MA. Intellectual content: MA, RR. Supervision: MAC.

Funding
The author received no financial support for this article.

Availability of data and materials
All data can be made available upon request to corresponding author.

Declarations

Ethics approval and consent to participate
Not applicable.

Consent for publication
A written and informed consent was acquired from the guardian (mother) regarding names and evidence used in this publication.

Competing interests
The authors declare that they have no competing interests.

Received: 5 October 2023 Accepted: 14 November 2023
Published online: 07 December 2023

References

1. (WHO) WHO (2022) Global Situation of COVID-19. WHO Health Emergency Dashboard
2. Wang X, Chen X, Tang F, Luo W, Fang J, Qi C et al (2021) Be aware of acute kidney injury in critically ill children with COVID-19. Pediatr Nephrol 36(1):163–169
3. Lu X, Zhang L, Du H, Zhang J, Li YY, Qu J et al (2020) SARS-CoV-2 infection in children. N Engl J Med 382(17):1663–1665
4. Ling Y, Xu SB, Lin YX, Tian D, Zhu ZQ, Dai FH et al (2020) Persistence and clearance of viral RNA in 2019 novel coronavirus disease rehabilitation patients. Chin Med J 133(9):1039–1043
5. Hirsch JS, Ng JH, Ross DW, Sharma P, Shah HH, Barnett RL et al (2020) Acute kidney injury in patients hospitalized with COVID-19. Kidney Int 98(1):209–218
6. Dong Y, Mo X, Hu Y, Qi X, Jiang F, Jiang Z et al (2020) Epidemiology of COVID-19 among children in China. Pediatrics. 145(6):e20200702
7. Wong SH, Lui RN (2020) Covid-19 and the digestive system. J Gastroenterol Hepatol 35(5):744–8
8. Marand AJB, Bach C, Janssen D, Heesakkers J, Ghojazadeh M, Vögeli TA et al (2021) Lower urinary tract signs and symptoms in patients with COVID-19. BMC Infect Dis 21(1):706
9. Almeida FJ, Olmos RD, Oliveira DBL, Monteiro CO, Thomazelli LM, Durigon EL et al (2020) Hematuria associated with SARS-CoV-2 infection in a child. Pediatr Infect Dis J 39(7):e161
10. Abdool Karim SS, de Oliveira T (2021) New SARS-CoV-2 variants — clinical, public health, and vaccine implications. N Engl J Med 384(19):1866–1868
11. Hamming I, Timens W, Bulthuis M, Lely A, Navis GJ, van Goor H (2004) Tissue distribution of ACE2 protein, the functional receptor for SARS coronavirus A first step in understanding SARS pathogenesis. J Pathol 203(2):631–7
12. Cheng Y, Luo R, Wang K, Zhang M, Wang Z, Dong L et al (2020) Kidney disease is associated with in-hospital death of patients with COVID-19. Kidney Int 97(5):829–838
13. Chan L, Chaudhary K, Saha A, Chauhan K, Vaid A, Zhao S et al (2021) AKI in hospitalized patients with COVID-19. J Am Soc Nephrol 32(1):151–160
14. West CP, Montori VM, Sampathkumar P (2020) COVID-19 Testing: the threat of false-negative results. Mayo Clin Proc 95(6):1127–1129

Publisher's Note