Tan and Tan
Egyptian Pediatric Association Gazette (2023) 71:86
https://doi.org/10.1186/s43054-023-00233-3

Egyptian Pediatric Association Gazette

CASE REPORT

Open Access

A rare congenital anomaly in a female child with acute urinary retention—female hypospadias: a case report

Hooi Hooi Tan[1*] and Shung Ken Tan[2]

Abstract

Background Female hypospadias is a rare congenital anomaly and defined as a female urethral opening on the anterior vaginal wall. Diagnosis is challenging due to its rarity. Different anatomical variations exist depending on the location of the urethral opening. Clinical presentation can vary from asymptomatic until end-stage renal disease due to lower urinary tract obstruction. This case highlights the important clinical and radiological features of female hypospadias. Surgical treatment remains the mainstay management for this entity.

Case presentation We report a case of a 5-year-old girl presented with 3 days of lower abdominal pain, vomiting and difficulty in voiding. She was previously well. Abdominal examination revealed a palpable suprapubic mass arising from the pelvis up to the umbilicus. Perineal examination showed a single opening at the introitus. Ultrasound showed a grossly distended urinary bladder and bilateral mild hydroureteronephrosis. Catheterization of the opening failed to decompress the bladder, and a suprapubic catheter was inserted which drained 500 cc of clear urine. She also developed acute kidney injury which resolved after suprapubic drainage. Cystogram and genitogram failed to delineate the communication between the urinary bladder and vagina. However, cystovaginoscopy revealed a normal vagina opening, and the urethral meatus entered the anterior wall of the vagina distally. She underwent a meatoplasty and recovered well after surgery.

Conclusion Attention to important clinical and radiological features helps in the diagnosis of female hypospadias. Female hypospadias should be suspected in female patient with single opening at the introitus, acute urinary retention and failed urinary catheterization. Cystovaginoscopic examination is required to diagnose this condition. Urethroplasty is curative with good outcome for low type of female hypospadias.

Keywords Female hypospadias, Urinary bladder outlet obstruction, Urogenital sinus, Urethroplasty, Case report

Background

Female hypospadias is a very rare entity secondary to arrest of development of the urogenital sinus [1]. Female hypospadias is characterized by congenital female urethral opening on the anterior vaginal wall (proximal to the hymenal ring) anywhere between the introitus and the vaginal fornix [2]. Age of presentation and symptoms vary depending on the anatomy of the urethral opening in relation to the vaginal wall.

There are a few anatomical variants reported in the literature: (a) high vaginal ectopia of the external urethral opening, (b) low vaginal ectopia of the external urethral opening, (c) ectopia of the external urethral opening in the urogenital sinus, (d) vesicovaginal fusion of the neck of the urinary bladder with vagina accompanied with enuresis and (e) any of the above variants of female

*Correspondence:
Hooi Hooi Tan
hooi525@yahoo.com
[1] Department of Radiology, Hospital Seberang Jaya, Seberang Jaya, Perai, Pulau Pinang 13700, Malaysia
[2] Paediatric Surgery Unit, Department of Surgery, Hospital Seberang Jaya, Seberang Jaya, Perai, Pulau Pinang 13700, Malaysia

hypospadias in combination with false or true hermaphroditism [3, 4]. It is difficult to diagnose clinically as children can have variable clinical presentation. Patient can be asymptomatic until chronic renal failure due to lower urinary tract obstruction. Antenatal findings may show mild renal pelviectasis which is non specific, although difficulty in catheterization could help to get a correct diagnosis [5]. However, proper perineal examination in combination with a cystovaginoscopy is needed to diagnose this condition.

Treatment requires surgical correlation by transposition of the external urethral opening from the vagina to the perineum in sub clitoris location [1, 2]. Prognosis is good after surgical intervention.

Case presentation

A 5-year-old female presented with lower abdominal pain and distension for 3 days, vomiting and difficulty in voiding. Symptoms occurred acutely with initial dribbling of urine upon straining on the first day of illness followed by acute urinary retention for 2 days. She has no fever. Bowel opening was regular. Due to her poor socioeconomic background, she had no proper antenatal or postnatal follow-up. She was born term via spontaneous vaginal delivery at 38 weeks at home by a midwife. Patient was previously well with no history of recurrent hospital admissions for vaginal or urinary tract infections.

Examination of the abdomen revealed a huge palpable abdominal mass, arising from the suprapubic region up to the level of the umbilicus. The mass was smooth, firm in consistency and dull on percussion. Abdomen was non tender with no peritonism. Perineal examination showed a single opening at the introitus, and anus was normally located (Fig. 1). On digital rectal examination, an extraluminal mass can be felt compressing on the anterior rectal wall. Full blood count showed normal RBC, normal WBC and increased platelet. Renal profile was deranged with high serum urea (17.1 mmol/ L), high potassium (5.3 mmol/ L) and creatinine (349 mmol/ L). C-reactive protein was raised. VBG showed severe metabolic acidosis. Urinalysis was consistent with urinary tract infection evidenced by positive for nitrite and leucocytes.

Abdominal x-ray showed a central pelvic mass pushing the bowel loops to the periphery of the abdomen with no evidence of bowel obstruction. Ultrasound abdomen revealed a grossly distended urinary bladder with bilateral mild hydroureteronephrosis (Fig. 2). Catheterization of the perineal opening failed to drain the urinary bladder. Ultrasound-guided suprapubic catheter was inserted which drained 500 cc of clear urine. Patient's renal profile normalized after bladder drainage. Her acute kidney injury resolved.

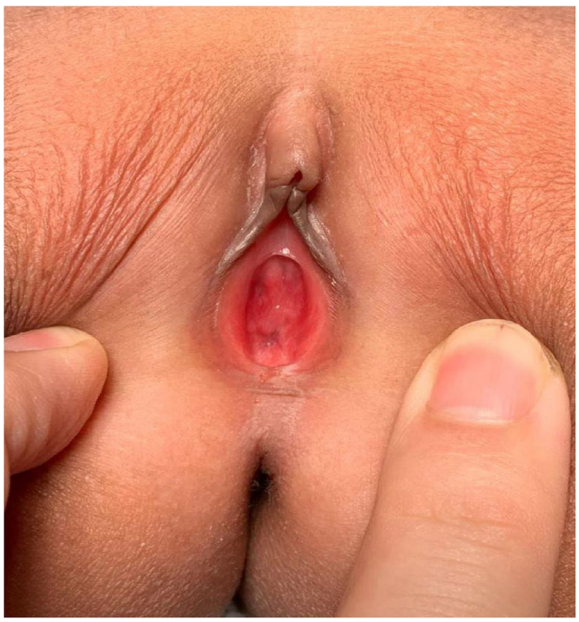

Fig. 1 Perineal examination showed a single opening at the introitus. Catheterization of the opening failed to decompress the bladder

Cystogenitogram showed a grossly distended bladder with trabeculations and a distended vagina suggestive of hydrocolpos. The communication between the urinary bladder and vagina was not demonstrated (Fig. 3). MRI was not performed for this patient. Cystovaginoscopy revealed a normal vagina opening with a single cervix. The urethral meatus was located at the anterior wall of the distal vagina superficial to the perineum. Distance of urethral meatus from the perineum was around 2 mm. Urethroscopy showed a long urethra around 2 cm with normal bladder neck. She underwent a meatoplasty (Fig. 4). The perineal surface, superficial to the urethral meatus, was laid open longitudinally up to the anterior urethra and sutured transversely to exteriorize and widen the meatus onto the perineal surface (Fig. 5). Postoperative recovery was uneventful. Suprapubic catheter was clamped, and she was allowed to void from below. During outpatient visit after 2 weeks, she was able to void normally. Hence, suprapubic catheter was removed. She was well at 2-month follow-up.

Discussion

Female hypospadias is characterized by ectopic dorsal location of the external urethral opening, which is a rare congenital malformation. It is defined as female urethral opening on the anterior vaginal wall (proximal to the hymenal ring) anywhere between the introitus and the vaginal fornix [2]. Solov'ev classified this entity as follows: (a) vestibular (partial), (b) vestibulovaginal (subtotal) and

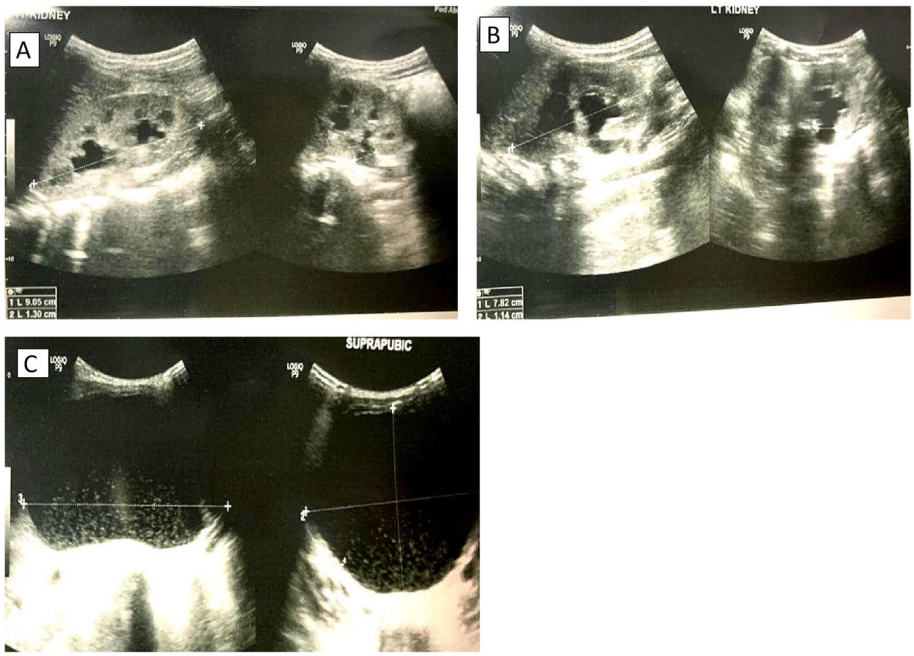

Fig. 2 **A** and **B** Ultrasound KUB showed bilateral mild hydronephrosis and proximal hydroureter. **C** Ultrasound KUB showed distended urinary bladder with internal moving debris

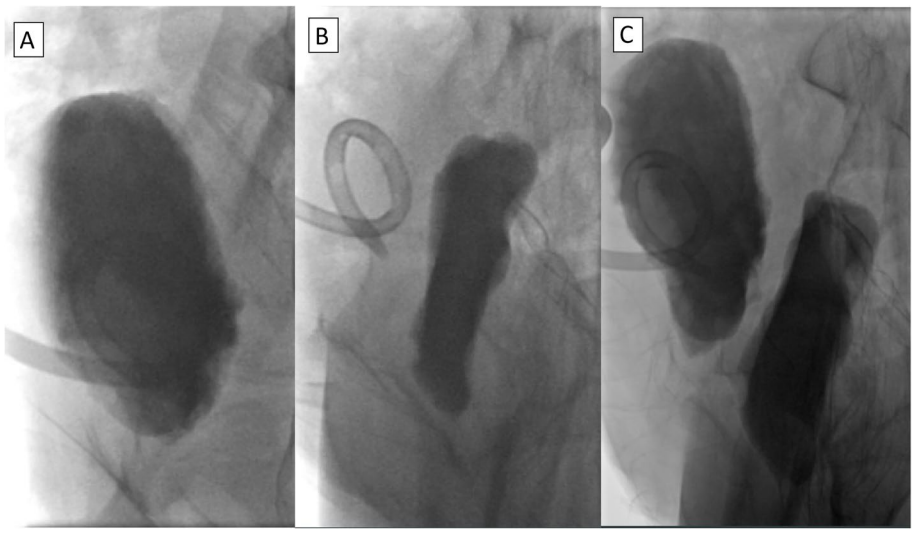

Fig. 3 **A** Cystogram showed distended urinary bladder with trabeculated in outline. **B** Genitogram showed contrast opacification of vagina. **C** Cystogenitogram failed to delineate the communication between the urinary bladder and vagina

(c) vaginal (total) types [6]. Knight H. M. reported clinical classification which consists of complete (type 1) and incomplete (type 2); urethral subtypes are IIa, short wide, and IIb, normal urethral diameter [7]. Three groups have been divided by Blum: (1) a longitudinal communication between the posterior urethral wall and the anterior vaginal wall; (2) a persistent urogenital sinus, where the vagina enters into the urethra but the hymen lies deep in the urogenital sinus; and (3) the urethra opening into the vagina proximal to a normal hymen [8]. Other differential diagnosis would be a cloaca or posterior cloaca. In a cloaca, the urogenital and rectum join to form a single canal and can be identified as a single perineal opening without a normal anus. In a posterior cloaca, the urogenital

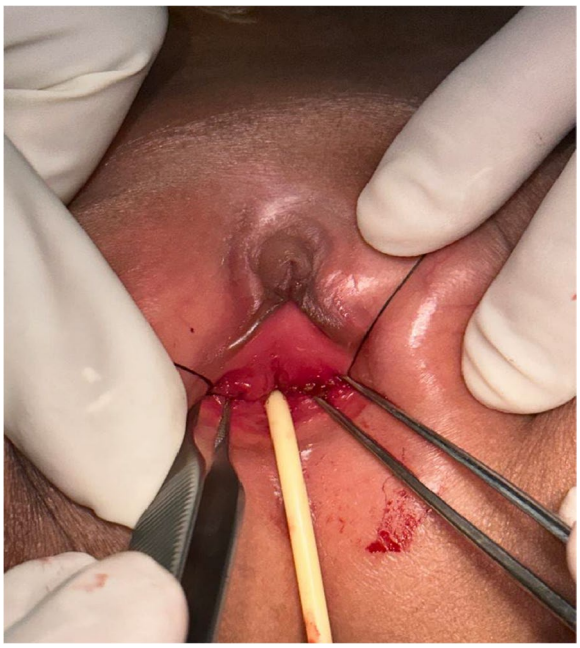

Fig. 4 Showing ureteric catheter in urethral opening transposed anteriorly and superficially after anterior meatoplasty

canal opens into the anterior wall of a normally located anorectum.

Hypospadias occurs in both sexes with a male gender preference. True pathoetiology of female hypospadias remains obscure [2]. Lower part of the urogenital sinus forms the common origin of the distal part of vagina and urethra. Abnormal development of these structures may result in female hypospadias [9]. Female hypospadias may coexist with other congenital urogenital septal defect, such as vaginal atresia, vaginal septum and bicornuate uterus [2]. Association with other anomalies like urethral duplication, 46XX disorders of sexual development (DSD), cloacal malformation and non-neurogenic neurogenic bladder has been reported [1, 10]. In this case report, patient has isolated female hypospadias without other congenital anomaly, which is very rare.

Yogesh suggested that description of female hypospadias should be used for the condition which is external urethral opening located in the lower one-third of the vagina. The entity which is external urethral orifice located in the upper two-thirds of vagina should designate as persistent urogenital sinus [10]. The urethral calibre will decide the prognostic significance. The shorten distance between the external urethral orifice and vaginal vestibule most likely to have normal calibre of urethra and less clinical complaints [10]. Narrower urethral lumen and higher location of the urethral orifice on the anterior vaginal wall, which is closer to the vaginal fornix, frequently result in urinary bladder outlet obstruction like acute urinary retention, hydroureteronephrosis, bladder distention, obstructive nephrolithiasis, and urinary tract infection [10]. Although our patient has short distance of urethral meatus from the perineum (2 mm), she was having severe symptoms of urinary bladder outflow obstruction complicated with acute renal failure. We postulate that this may be due to a urine filled hydrocolpos compressing on to the bladder neck.

Age of presentation may vary from paediatric age group to adults. The clinical presentation of female hypospadias is variable. Patients can be asymptomatic and incidentally discovered due to unsuccessful catheterization of urinary bladder. Patients may present with poor

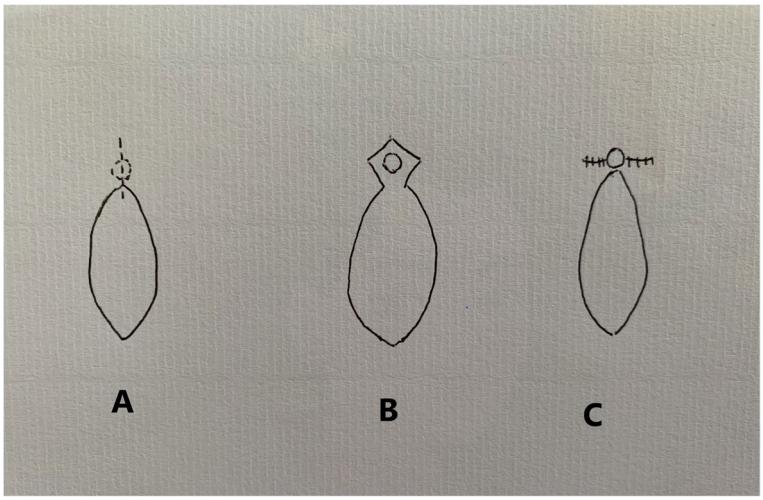

Fig. 5 **A** Longitudinal incision on the perineal surface superficial to the urethral meatus at the anterior vaginal wall. **B** Meatus exposed after laying open the anterior vaginal wall. **C** Transverse closure of the incision to transpose the meatus superficially and anteriorly

urine stream, post micturition incontinence, vaginal voiding, recurrent urinary tract infection (UTI), urethral syndrome and dyspareunia [2]. Postpartum stress incontinence, total incontinence after delivery, detrusor sphincter dyssynergia, and vaginal voiding which leads to urinary leakage secondary to frequent intense sphincter contraction as well as vaginal stone formation have been reported in patient with female hypospadias [2]. Sexual intercourse may worsen urethral syndrome and UTI. Hill et al. reported fibrosis secondary to urethral surgery or atrophic vaginitis as other acquired causes of female hypospadias in the adult age group [9].

Antenatal scan may reveal normal study of KUB or mild and non-specific renal pelviectasis. Abdominal radiograph may show non-specific features and is not helpful for diagnosis of FH. Ultrasound abdomen should be the first diagnostic modality. Ultrasound may show bilateral hydroureteronephrosis with distended urinary bladder in FH patient represented with lower urinary tract obstruction. Concomitant urolithiasis, internal debris in pelvicalyceal system and thickened urinary bladder wall can occur together in view of prolonged urine stasis. The degree of obstructive uropathy is most likely related to calibre of the external urethral orifices. We proposed that larger urethral opening results to lesser degree of obstructive uropathy. In addition, ultrasound can help to assess other genital abnormality.

Antegrade cystogram via a suprapubic catheter could reveal an abnormal course of the urethra leading into the vagina. Genitogram may show opacification of the vagina without delineating the urethra. In the case of this patient, cystogram and genitogram failed to delineate the communication between the urinary bladder. Therefore, negative findings of cystogram and genitogram cannot totally exclude the diagnosis of FH. Computed tomography is less suitable to delineate the soft tissue plane between the pelvic organs. Furthermore, unnecessary radiation exposure should be avoided in children. MRI would be a more suitable modality to demonstrate the anatomy of the bladder, urethra and vagina. Advancement in 3D reconstruction technologies could enable clinicians to differentiate various urogenital anomalies [11]. MRI was not done in our patient due to financial constrains faced by her parents.

In this instance, a cystovaginoscopy was needed to map out the anatomy of her genitourinary system and come to a conclusion of FH.

There are various methods to repair female hypospadias. All variants of FH may be surgically corrected by transposition of the external opening of the urethra from the vagina to the perineum in sub clitoris location. Amilal Bhat et al. reported that vaginal flap urethroplasty with stone removal was performed in a case of FH with vaginal stones [2]. In case of aplasia or hypoplasia of urethra, tubularization of anterior vaginal strip to construct the urethra was reported [12]. Meatoplasty [13], construction of urethra from vaginal wall with buttock flap [14] or perineal flap [15] as well as pedicle flap of labial and bulbocavernosus muscle [10] could be other surgical methods. In our patient, due to the superficial location of the metal opening in relation to the perineum, an anterior meatoplasty was adequate to transpose the meatus to the surface and anteriorly. A longitudinal incision was on the anterior vaginal wall up to the meatal opening, and the incision was sutured transversely.

Conclusion

Female hypospadias is a rare entity in the paediatric age group. Diagnosis can be challenging and go unnoticed. It is usually diagnosed during catheterization for other condition or lower urinary tract endoscopy. Single introitus, clinical presentation like urethral syndrome, recurrent UTI and bladder outlet obstruction with radiological features of obstructive uropathy may help to get the correct diagnosis. It is important to check three perineal openings in initial female neonatal examination to avoid missing this congenital abnormality. Meatoplasty and genital reconstruction with different flaps are the surgical treatment. Outcome is favourable after surgical procedure to reduce risk of renal failure.

Abbreviations

FH	Female hypospadias
RBC	Red blood cell
WBC	White blood cell
VBG	Venous blood gas
DSD	Disorders of sexual development
UTI	Urinary tract infection

Acknowledgements

Nil

Authors' contributions

THH, conception, design of the work, acquisition, analysis of the data and preparation of the manuscript. TSK, acquisition and analysis of the data, drafting and critical review. All authors have read and approved the final manuscript.

Funding

Nil

Availability of data and materials

All data generated or analysed during this study are included in this published article.

Declarations

Ethics approval and consent to participate

Not applicable.

Consent for publication

Written consent had been obtained from the parent of study participant.

Competing interests
The authors declare that they have no competing interests.

Received: 11 October 2023 Accepted: 8 November 2023
Published online: 15 November 2023

References

1. Bavadiya G, Shah C, Sarkar KK, Ghoshal P, Pathak H, Sarkar K (2020) Unusual presentation of female bladder outlet obstruction- female hypospadias with urethral stenosis. Urol Case Rep 8(32):101243. https://doi.org/10.1016/j.eucr.2020.101243
2. Bhat A, Saxena R, Bhat MP, Dawan M, Saxena G (2010) Female hypospadias with vaginal stones: a rare congenital anomaly. J Pediatr Urol 6(1):70–74. https://doi.org/10.1016/j.jpurol.2009.03.014
3. Derevianko IM, Derevianko TI, Ryzhkov VV (2007) Hypospadia in females. Urologiia 3:26–28
4. Mildenberger H, Bürger D, Habenicht R (1988) Kinder- chirurgie Die Hypospadie beim Mädchen Female Hypospadias. Eur J Pediatr Surg 1988 43(1):35–37. https://doi.org/10.1055/s-2008-1043409
5. Elder JS et al (1998) In: Walsh Patrick C (ed) Congenital anomalies of the genitalia, vol 2. Campbell's urology, p 2138
6. Solov'ev AE (1993) Diagnostika i lechenie gipospadiĭ u devochek [The diagnosis and treatment of hypospadias in girls]. Urol Nefrol (Mosk) 6:11–13
7. Knight HM, Phillips NJ, Mouriquand PD (1995) Female hypospadias: a case report. J Pediatr Surg 30(12):1738–1740. https://doi.org/10.1016/0022-3468(95)90469-7
8. Blum V (1904) Die hypospadie der weiblichen Harnohre. Monatsber Urol 9:522e44
9. Hill JT, Aker M, Fletcher MS, Yates-Bell AJ (1982) Female hypospadias. Case reports. Br J Obstet Gynaecol 89(7):581–583. https://doi.org/10.1111/j.1471-0528.1982.tb03664.x
10. Sarin YK, Kumar P (2019) Female hypospadias-need for clarity in definition and management. J Indian Assoc Pediatr Surg 24(2):141–143. https://doi.org/10.4103/jiaps.JIAPS_69_18
11. Gang S, Song SH, Kwon J, Kwon H, Ha S, Park J, Kim N, Yoon HM, Namgoong JM (2023) Case report: magnetic resonance imaging-based three-dimensional printing for reconstruction of complex cloacal malformations. Front Pediatr 7(11):1103401. https://doi.org/10.3389/fped.2023.1103401
12. Belman AB (1985) In: Kelalis PP, King LR, Belman AB (eds) Urethra, vol 2. Clinical paediatric urology, p 786
13. Van Bogaert LJ (1992) Surgical repair of hypospadias in women with symptoms of urethral syndrome. J Urol 147(5):1263–1264. https://doi.org/10.1016/s0022-5347(17)37536-5
14. Hendren WH (1998) Construction of a female urethra using the vaginal wall and a buttock flap: experience with 40 cases. J Pediatr Surg 33(2):180–187. https://doi.org/10.1016/s0022-3468(98)90428-6
15. Hendren WH (1980) Construction of female urethra from vaginal and perineal flap. J Urol 123:657–664. https://doi.org/10.1016/S0022-5347(17)56077-2

Publisher's Note