AbdelMassih *et al.*
Egyptian Pediatric Association Gazette (2023) 71:68
https://doi.org/10.1186/s43054-023-00212-8

Egyptian Pediatric Association Gazette

RESEARCH

Open Access

Sphericity index for bedside diagnosis of acute myocarditis

Antoine AbdelMassih[1,2*], Sonia El-Saiedi[1], Rana Hendawy[1], Reem Esmail[1], Manal AbdelHameed[1], Alaa Sobeih[1], Ahmed Kharabish[3], Nourine Diab[4], Hanya Gaber[5], Nadine El-Husseiny[6,7] and Hala M. Agha[1]

Abstract

Background Differentiating acute myocarditis (AMY) from dilated cardiomyopathy (DCM) in a patient presenting with acute heart failure and poor systolic function is of utmost importance to initiate timely anti-inflammatory treatment in AMY. Using cardiac magnetic resonance (CMR) or endomyocardial biopsies (EMB) as gold standards might be limited due to the likelihood of hemodynamic compromise. Eccentric myocardial remodeling as measured by sphericity index (SPI) might be useful in differentiating AMY from DCM, due to the progressive increase in transverse LV diameter in DCM. The primary outcome parameter of our study was to test the diagnostic accuracy of SPI in the differentiation of AMY from DCM, while the secondary outcome parameter was to compare the diagnostic accuracy of SPI to troponin I in the same context. For this purpose, we conducted a retrospective study involving a chart review of the files of sixty patients admitted with acute heart failure due to hypokinetic left ventricle in our hospital. Patients were divided after CMR imaging into two groups: group 1 with AMY ($n=30$) and group 2 with DCM ($n=30$). Demographic and clinical characteristics of the patients, including heart rate, need for mechanical ventilation, use of milrinone, epinephrine and norepinephrine, troponin I, and 2D-derived sphericity index, were collected from patients' files.

Results Patients with AMY had a higher need for mechanical ventilation inopressors and vasopressors; 73% of AMY patients required mechanical ventilation and epinephrine use, compared to less than 50% of DCM patients. Troponin I elevation was more marked in AMY compared to DCM patients (0.25 ± 0.04 vs. 0.21 ± 0.03, respectively). SPI was significantly higher in DCM compared to AMY cases, denoting a spherical configuration of the myocardium acquired due to progressive remodeling, because of the chronicity of the pathology. ROC analysis revealed that an $SPI \leq 0.38$ was 100% sensitive in differentiating DCM from AMY, compared to a 53% sensitivity with the commonly used troponin I.

Conclusion AMY diagnosis can be achieved by the assessment of sphericity index rather than troponin I. The bedside nature and noninvasiveness of SPI should reshape the practice in this context. SPI assessment can be part of point-of-care echocardiography, taught to emergency room (ER) physicians and intensivists.

Keywords SPI, De novo remodeling, Myocarditis, DCM

*Correspondence:
Antoine AbdelMassih
antoine.abdelmassih@kasralainy.edu.eg
Full list of author information is available at the end of the article

Background

Acute myocarditis (AMY) is involving myocardial injury by inflammation whether infectious (mostly viral) or due to chronic systemic autoimmune disorders [1].

Idiopathic dilated cardiomyopathy (DCM) (after exclusion of systemic disease or medication) affecting the myocardium is not an uncommon sequela of acute myocarditis (21 to 60%). Compared to myocarditis, it is characterized by the absence of viremia or intramyocardial inflammation on myocardial biopsy. It is regarded that autoimmune self-perpetration due to molecular mimicry is the main mechanism of the persistent damage to the myocardium in such patients [2].

Both might commonly present with acute heart failure with echocardiographic evidence of poor left ventricular (LV) systolic functions (fractional shortening) by conventional echocardiography; however, differentiating both entities is of utmost importance as patients with acute myocarditis might benefit from therapy models such as intravenous immunoglobulins, azathioprine, or others, while patients with any chronic myocarditis/dilated cardiomyopathy will lose the opportunity of responding to anti-inflammatory therapy. It seems that, if not treated in due time, once the cascade of cardiac remodeling induced by untamed inflammation starts, such remodeling might persist forever [3].

The "all-time" gold standard for differentiation between AMY and DCM is the endomyocardial biopsy (EMB), it can easily discriminate the presence or absence of inflammation, and it can as well show the type of cellular infiltration. However, EMB is not easy to be performed in unstable patients presenting with hemodynamic compromise. Nevertheless, EMB tools are not always present or available, especially in less fortunate, developing countries. This led to the adoption of Lake Louise criteria for cardiac magnetic resonance (CMR)-guided diagnosis of AMY. Lake Louise criteria became the more available gold-standard tool for diagnosis of acute myocarditis [4]. These criteria have been updated by Baeßler et al. [5] to achieve a better diagnostic accuracy with a sensitivity of 94% against the benchmark endomyocardial biopsy. However, CMR remains a non-bedside, costly tool despite its accuracy. The cost of CMR setting, as well as the hazards of mobilizing a patient with hemodynamic compromise, poses a great challenge in implementation of CMR as a wide-base tool for diagnosis of acute myocarditis and the early implementation of therapy.

Both CMR and EMB rely on the distinction between acute myocarditis and dilated cardiomyopathy in the detection of evidence for inflammation.

Cardiac enzymes also can play a role in differentiation; troponins are an indicator of myocyte injury. They are characteristically elevated in acute myocarditis and are sometimes used for risk stratification. Cardiac troponins also have a negative prognostic role in the setting of DCM. Troponins are not consistently elevated in DCM and can also be normal in myocarditis. Elevation of troponins in the setting of acute heart failure in children is usually interpreted as an indicator of myocarditis, but this overlooks the possible elevation of troponins in DCM. In a large retrospective study by Yoldas and Orlun, they confirmed that 46% of patients presenting with elevated troponins had myopericarditis compared to 15% who had DCM as the underlying pathology [6].

In this aspect, the role of echocardiography in differentiating dilated cardiomyopathy from myocarditis is limited. Case reports such as De Bella et al. series, Smedema et al., and Thuny et al. postulate a role for new techniques such as strain and tissue Doppler in pointing at inflammation. However, these studies or others cannot still deny that echocardiography cannot differentiate early inflammation from scar formation, which is the most important clue in the differentiation between both entities [7–9].

The differentiation of myocarditis from DCM can rely, as well, on the extent of remodeling; remodeling is a constant for the diagnosis of dilated cardiomyopathy. DCM derives its name from the eccentric remodeling involving its course. To our knowledge, only one study to date has weighed the extent of remodeling in myocarditis; Mendes et al., in his series, concluded that remodeling happens in myocarditis as early as 5 days after the clinical presentation of the patient. However, no study to date examined the extent of remodeling during the first day of clinical presentation and its ability to discriminate between the two entities [10].

The primary outcome parameter of this study was to test the diagnostic accuracy of simple bedside parameter, namely 2D sphericity index (SPI), in the differentiation of acute myocarditis from dilated cardiomyopathy against standard recent benchmark criteria of CMR. The secondary outcome parameter was to compare the diagnostic accuracy of SPI to other predictors, such as serum troponin I.

Methods

Type of study and study subjects

This retrospective cross-sectional study included a chart review of all patients presenting with the following:

- Acute heart failure, defined as new or worsening signs of heart failure that warranted an emergency visit and hospitalization
- Echocardiography proof of a poorly contracting dilated LV

- In the absence of any preceding history of congenital heart disease or acquired heart lesions, the patients' data, including their echocardiographic exams, were recruited from the pediatric emergency room and upon admission to the pediatric intensive care unit (PICU) of our hospital, through a period between September 2021 and September 2022.

Exclusion criteria included the following:

Delay in CMR performance due to technical, clinical, or administrative reasons for 48 h after presentation
Delay in troponin I testing or echocardiographic examination for 24 h after presentation
Preceding history of congenital heart disease, acquired heart lesions, or any extracardiac disease or medications that can affect myocardial functions
Inability to retrieve required echocardiographic data
Any evidence of Kawasaki disease or other systemic disease that can impact myocardial functions

Patients were divided into two groups as follows:

- *Group 1 with cardiac magnetic resonance evidence of acute myocarditis* using the following cutoffs: (1) positive late gadolinium enhancement, (2) $\geq -25\%$ for global circumferential strain of LV GCS_{LV} by CMR feature tracking (FT)-based strain analysis, and (3) the mean absolute deviation of segmental pixel SD (madSD) by T2 mapping ≥ 1.8 ms. The aforementioned criteria were suggested by Baeßler et al. [5] as the latest update to Lake Louise criteria for defining acute myocarditis by CMR.
- *Group 2 without the mentioned criteria*

Methods

Patients' files (total of 60 patients) meeting the mentioned inclusion and exclusion criteria underwent the following:

Retrieval of the following data:

Demographic and clinical data such as age, sex, parent consanguinity, family history of myocardial disease, body surface area (BSA), and the absence or presence of viral prodrome and heart rate
PICU data including need for mechanical ventilation, milrinone, epinephrine, and norepinephrine
Serum level of *troponin I* (within 24 h of admission)

- Cardiac troponin I was quantitatively determined with immunoenzymoluminometric assay, which operates at the picomolar concentration range. The lower limit of detection of the assay is 3 pg/mL. This sensitivity is obtained by the use of a luminescent substrate and modification of a previously described and extensively validated enzyme immunoassay based on two different monoclonal antibodies (MAbs). This was done via human cardiac troponin I ELISA kit (ab200016), a single-wash 90-min sandwich ELISA designed for the quantitative measurement of cardiac troponin I.

Baseline bedside echocardiography parameters (within 24 h of admission) including left ventricular end-diastolic dimension, fractional shortening, and sphericity index (SPI)

SPI was measured offline by two independent researchers, blinded to the patient's history and condition. LVSI was calculated as LV basal radial length/longitudinal length, measured in both the apical 4- and 2-chamber views during end diastole (ED) and end systole (ES). An average of four measurements was reported (Fig. 1) [11].

It is worth mentioning that this study followed the "HOPE" initiative of our pediatric cardiology unit, which involved performing CMR to all patients with poor myocardial functions, to determine, their suitability for cardiac transplantation, which is unavailable in our center. After screening them using CMR and echocardiography, the suitable candidates were sent to international centers with transplant expertise. Our study involved retrograde comparison of the results of CMR done for these patients and the retrieval of available echocardiographic measurements. Sphericity index was not routinely measured, but the available recorded echocardiographic clips allowed its offline measurement in all patients, as previously detailed in the methodology.

Statistical analysis

Data were analyzed using MedCalc statistical software and Microsoft Excel. Normally distributed numerical variables were presented as mean and standard deviation (SD), and inter-group differences were compared using the unpaired *t*-test.

Categorical data were compared using the chi-square test or Fisher test.

Multivariate analysis was performed to determine the best independent variable discriminating dilated cardiomyopathy from myocarditis.

Receiver operating characteristic curve (ROC) analysis and interactive dot diagrams were performed to describe the diagnostic accuracy and cutoffs of sphericity index and troponin I in the distinction of acute myocarditis

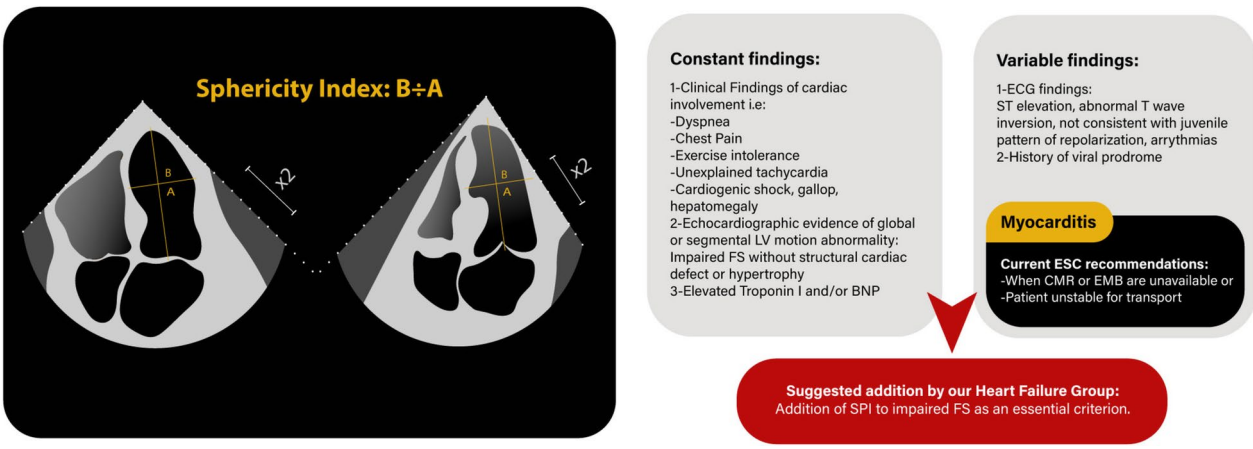

Fig. 1 Diagrammatic illustration of sphericity index measurement and the suggested additive role to current European Society of Cardiology guidelines for diagnosis of acute myocarditis. Abbreviations: BNP, brain natriuretic peptide; CMR, cardiac magnetic resonance; ECG, electrocardiogram; EMB, endomyocardial biopsy; ESC, European Society of Cardiology; FS, fractional shortening; LV, left ventricle; SPI, sphericity index, B is the transverse diameter of the LV and A is the vertical diameter

from DCM. *P*-value < 0.05 was considered statistically significant.

Results

Our study included sixty patients divided into two groups: thirty acute myocarditis (AMY) patients and thirty DCM patients (Table 1). There was no statistical difference in age or sex distribution between the two study groups; the mean age of myocarditis patients was 2.1 ± 0.2 compared to a mean of 2.3 ± 0.4 in DCM cases.

Neither viral prodrome nor parent consanguinity (suggestive of DCM) was able to differentiate between the two study groups (Table 1).

Table 1 Demographic, clinical characteristics, troponin I PICU, and bedside echocardiographic data of the 2 study groups

Variable		Group 1 Acute myocarditis (*n* = 30)	Group 2 DCM (*n* = 30)	*p*-value
Age (years) (mean ± SD)		2.1 ± 0.2	2.3 ± 0.4	0.383
Sex (M/F) (*n*)		17/13	18/12	1.000
Parent consanguinity (*n*/%)		5 (41%)	7 (38%)	1.000
BSA (m^2) (mean ± SD)		0.48 ± 0.01	0.47 ± 0.02	0.436
History of viral prodrome (*n*/%)		7 (58%)	6 (40.0%)	0.657
Heart rate (bpm) (mean ± SD)		137 ± 4	138 ± 4	0.39
Temperature (°C) (mean ± SD)		37.5 ± 0.4	37.6 ± 0.2	**0.56**
Lower limb edema (*n*/%)		0 (0.0%)	2 (11%)	0.02
Troponin (ng/ml) (mean ± SD)		0.25 ± 0.04	0.21 ± 0.03	< 0.001
Mechanical ventilation		22 (73%)	14 (47%)	0.003
Inotropes used	Milrinone	30 (100%)	30 (100%)	1
	Epinephrine	22 (73%)	13 (43%)	< 0.001
	Norepinephrine	6/30 (20%)	2/30 (7%)	0.003
LVEDD (mm) (mean ± SD)		39 ± 3.5	47 ± 4.9	< 0.001
FS (%) (mean ± SD)		24 ± 1.7	21 ± 2.8	< 0.001
SPI (mean ± SD)		0.35 ± 0.01	0.45 ± 0.02	< 0.001

BSA Body surface area, *BPM* Beats per minute, *F* Female, *FS* Fractional shortening, *LVEDD* Left ventricular end-diastolic dimension, *M* Male, *n* Number, *SD* Standard deviation, *SPI* Sphericity index

Tachycardia was almost equally seen in both groups with a mean HR of 137 ± 4 in myocarditis patients compared to 138 ± 4 in DCM patients (Table 1).

Regarding PICU data, hemodynamic compromise was more evident in myocarditis cases compared to patients with DCM. Our results showed that patients with acute myocarditis had a higher need for mechanical ventilation inopressors and vasopressors; 73% of AMY patients required mechanical ventilation and epinephrine use, compared to less than 50% of DCM patients.

Troponin I elevation was more marked in AMY compared to DCM patients (0.25 ± 0.04 vs. 0.21 ± 0.03, respectively) (Table 1).

Table 2 Multivariate regression for the determination of the best predictor of acute myocarditis in the setting of a hypokinetic left ventricle in a patient admitted with acute heart failure

	t-stat	*p-value*
Use of norepinephrine	0.331338	0.74
Use of milrinone	65,535	0.78
Troponin I	−0.91369	0.8
HR	0.337802	0.73
LVEDD	3.030569	0.003
SPI	10.23874	< 0.001
FS	−2.37433	0.02

FS Fractional shortening, *LVEDD* Left ventricular end-diastolic dimension, *SPI* Sphericity index

LV dilation with subsequent increase in SPI was significantly higher in DCM compared to AMY cases (0.45 ± 0.02 vs. 0.35 ± 0.01) respectively, denoting the acquisition of a spherical configuration of the myocardium due to progressive remodeling, which is a result of the chronicity of the pathology in patients with DCM.

Multivariate regression showed that the best variable for discrimination between the two study groups was SPI (Table 2). A receiver operating characteristic analysis revealed that an $SPI \leq 0.38$ (Fig. 2) was 100% sensitive in differentiating DCM from AMY, compared to a 53% sensitivity with the commonly used troponin I (Fig. 3).

Discussion

Presenting with elevated cardiac troponins and heart failure or chest pain does not pose as much controversy in diagnosis in adults as in pediatric age group.

In adults, acute coronary syndrome is the most important cause of such presentation, while in children, myocarditis might account for most cases, but there are multiple other diagnoses that can be missed in the same context, notably dilated cardiomyopathy [6].

To date, there have been no studies comparing the extent of troponin elevation in acute heart failure patients due to myocarditis compared to dilated cardiomyopathy and on how to overcome this diagnostic challenge.

Our study confirmed that troponin I is significantly higher in myocarditis compared to DCM; however, its sensitivity was poor (53%) which raises the need for other bedside clinical or echocardiographic predictors.

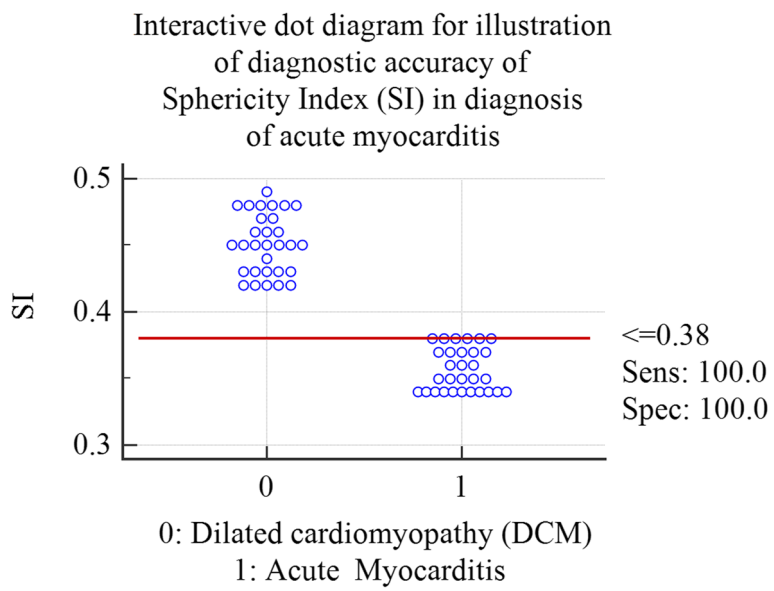

Fig. 2 Interactive dot diagram for illustration of diagnostic accuracy of sphericity index in diagnosis of acute myocarditis. Abbreviations: 0, dilated cardiomyopathy group; 1, myocarditis group; Sens, sensitivity; SPI, sphericity index; Spec, specificity

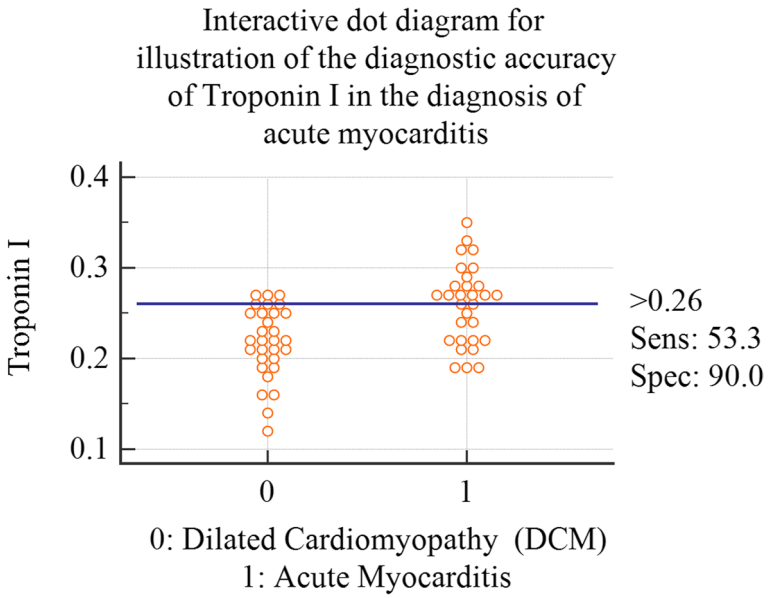

Fig. 3 Interactive dot diagram for illustration of diagnostic accuracy of troponin I in diagnosis of acute myocarditis. Abbreviations: 0, dilated cardiomyopathy group; 1, myocarditis group; Sens, sensitivity; Spec, specificity

The need for vasopressors was more pronounced in the myocarditis group, which outlines an important difference between de novo heart failure (DNHF) and acute decompensated chronic heart failure (ADCHF). As outlined by Raffaello and colleagues, patients with DNHF usually present with cardiogenic shock, while ADCHF cases are more likely to present with exacerbation of dyspnea and orthopnea due to pulmonary congestion. The rapidity of development of heart failure in DNHF does not allow enough time for compensatory mechanisms to support systemic circulation, hence the higher need for inotropes and vasopressors in DNHF, such as our myocarditis patients [12].

Myocardial remodeling represents a group of cellular, molecular, and conformational changes in the myocardium that occur in response to any myocardial stressor, ranging from inflammation to ischemia. The results of such changes are detrimental to the function of the myocardium as it impairs the contractile forces of the muscle and impairs its macro and micromechanics. Two main types of remodeling have been described: eccentric and concentric remodeling, which are surrogate names for dilatation and hypertrophy respectively [13].

Dilated cardiomyopathy imports its famous name from the eccentric remodeling process occurring in its context and the gradual transformation of the myocardium from a cylindrical shape to a rather spherical shape during this process. Despite the similarities that can exist in the clinical presentation between DCM and AMY, there is no definite data about the extent of myocardial remodeling in acute myocarditis.

In our study, the sphericity index was significantly higher in cases with DCM than in cases with acute myocarditis. The SPI recorded a sensitivity of 100% and a specificity of 97% in discrimination between both groups. This goes in disagreement with the Mendes et al. series, which states that sphericity index cannot be used reliably for detection of acute myocarditis. The difference observed might be explained by the delay in echocardiography after clinical presentation in Mendes et al. series, which recorded a mean of 5 days [10].

Finally, yet importantly, multivariate analysis, comparing the need for vasopressors, troponin I, and SPI in differentiating myocarditis and DCM, in the setting of acute heart failure, showed that SPI was the best predictor of acute myocarditis.

The recommendations of European Society of Cardiology (ESC) state that in areas where there is no availability of CMR or EMB, or if the patient's hemodynamic compromise might endanger his/her transport, diagnosis of myocarditis should rely on manifestations of heart failure or chest pain alongside elevated cardiac enzymes and echocardiographic evidence of LV dysfunction. We suggest adding to these criteria an $SPI \leq 0.38$ as evidence of an acute rather than chronic process [14, 15] (Fig. 1).

It is also worth mentioning that advanced echocardiographic segmental techniques, notably speckle-tracking echocardiography, can offer an additional tool for diagnosis of acute myocarditis. However, the cost of the

software and the expertise level needed to use them do not allow them to be used in daily bedside practice [16].

Limitations of our study was the inability to retrieve full cardiac magnetic resonance imaging data and full clinical and echocardiographic data from patients' files. Improvement of patients' records is a point to be raised in our institution; this will allow larger studies and stronger conclusions to be drawn, in view of the high flow of patients presenting to our facility.

Conclusions

This study underlines several new findings; it demonstrates that measuring the extent of myocardial remodeling and SPI assessment can be of utmost usefulness in the differentiation between acute myocarditis and dilated cardiomyopathy. Assessment of SPI can easily be taught to pediatric intensivists as part of the point-of-care echocardiography, and this can hasten the administration of intravenous immunoglobulin to AMY patients, increasing their chances of recovery.

It also showed that troponin I is not a sensitive marker in discrimination between myocarditis and DCM. Interestingly, it also showed that the need for vasopressors in pediatric acute heart failure can differentiate causes of de novo acute heart failure, such as myocarditis, from decompensated chronic heart failure occurring in DCM.

Larger sample sizes are needed to validate the use of SPI as a simple, bedside, and noninvasive parameter for differentiation of acute myocarditis from DCM.

Abbreviations

AMY	Acute myocarditis
DCM	Dilated cardiomyopathy
SPI	Sphericity index
ER	Emergency room
CMR	Cardiac magnetic resonance
LV	Left ventricle
PICU	Pediatric intensive care unit
EMB	Endomyocardial biopsy

Acknowledgements

To everyone who is seen as "a black sheep" and feeling stranger and shall rather be included and appreciated.

Authors' contributions

AA, SES, and HA contributed in the conception of the idea. AA, SES, RH, RE, MAH, AS, AK, ND, HG, NH, and HA contributed equally to drafting and revision of the manuscript. All authors read and approved the final manuscript.

Funding

This research received no specific grant from any funding agency, commercial, or not-for-profit sectors.

Availability of data and materials

Data cannot be shared to protect the privacy of participants.

Declarations

Ethics approval and consent to participate

This study received an approval from the Institutional Review Board of Pediatrics' Department, Cairo University. The study involved a chart review of anonymous patients' files with the respective diagnoses mentioned in the manuscript which was deemed not necessary for a consent to participate from patients' caregivers.

Consent for publication

Not applicable.

Competing interests

The authors declare that they have no competing interests.

Author details

[1]Pediatric Cardiology Unit, Department of Pediatrics, Cairo University Children Hospital, Cairo University, Cairo, Egypt. [2]Pediatric Cardiology Division, Cardiac Sciences' department, Sheikh Khalifa Medical City, Abu Dhabi, United Arab Emirates. [3]Department of Radiology, CMR Unit, Cairo University, Kasr Al Ainy, Cairo, Egypt. [4]Faculty of Medicine, Students' and Interns' Research Program, New Giza University, Cairo, Egypt. [5]Faculty of Medicine, Students' and Interns' Research Program, Cairo University, Cairo, Egypt. [6]Faculty of Dentistry, Cairo University, Cairo, Egypt. [7]Pixagon Graphic Design Agency, Cairo, Egypt.

Received: 12 July 2023 Accepted: 1 September 2023
Published online: 15 December 2023

References

1. Freedman SB, Haladyn JK, Floh A, Kirsh JA, Taylor G, Thull-Freedman J (2007) Pediatric myocarditis: emergency department clinical findings and diagnostic evaluation. Pediatrics 120(6):1278–1285. https://doi.org/10.1542/peds.2007-1073
2. Herman DS, Lam L, Taylor MRG, Wang L, Teekakirikul P, Christodoulou D, Conner L, DePalma SR, McDonough B, Sparks E, Teodorescu DL, Cirino AL, Banner NR, Pennell DJ, Graw S, Merlo M, Di Lenarda A, Sinagra G, Bos JM, Ackerman MJ, Mitchell RN, Murry CE, Lakdawala NK, Ho CY, Barton PJR, Cook SA, Mestroni L, Seidman JG, Seidman CE (2012) Truncations of titin causing dilated cardiomyopathy. N Engl J Med 366(7):619–628. https://doi.org/10.1056/NEJMoa1110186
3. Masarone D, Valente F, Rubino M, Vastarella R, Gravino R, Rea A, Russo MG, Pacileo G, Limongelli G (2017) Pediatric heart failure: a practical guide to diagnosis and management. Pediatr Neonatol 58:303–312. https://doi.org/10.1016/j.pedneo.2017.01.001
4. Roach RC, Hackett PH, Oelz O, Bärtsch P, Luks AM, MacInnis MJ, Baillie JK, Achatz E, Albert E, Andrews JS, Anholm JD, Ashraf MZ, Auerbach P, Basnyat B, Beidleman BA, Berendsen RR, Berger MM, Bloch KE, Brugger H, Cogo A, Costa RG, Cumpstey A, Cymerman A, Debevec T, Duncan C, Dubowitz D, Fago A, Furian M, Gaidica M, Ganguli P, Grocott MPW, Hammer D, Hall D, Hillebrandt D, Hilty MP, Himashree G, Honigman B, Gilbert-Kawai N, Kayser B, Keyes L, Koehle M, Kohli S, Kuenzel A, Levine BD, Lichtblau M, Macdonald J, Maeder MB, Maggiorini M, Martin D, Masuyama S, McCall J, McIntosh S, Millet G, Moraga F, Mounsey C, Muza SR, Oliver S, Pasha Q, Paterson R, Phillips L, Pichon A, Pickerodt PA, Pun M, Rain M, Rennie D, Ri-Li G, Roy S, Verges S, dos Santos TBC, Schoene RB, Schoch OD, Singh S, Sooronbaev T, Steinback CD, Stembridge M, Stewart G, Stobdan T, Strapazzon G, Subudhi AW, Swenson E, Roger Thompson AA, van Patot MT, Twomey R, Ulrich S, Voituron N, Wagner DR, Wang S, West JB, Wilkes M, Willmann G, Yaron M, Zafren K (2018) The 2018 Lake Louise Acute Mountain Sickness Score. High Alt Med Biol 19(1):4–6. https://doi.org/10.1089/ham.2017.0164
5. Baeßler B, Treutlein M, Schaarschmidt F, Stehning C, Schnackenburg B, Michels G, Maintz D, Bunck AC (2017) A novel multiparametric imaging approach to acute myocarditis using T2-mapping and CMR feature tracking. J Cardiovasc Magn Reson 19:1–10. https://doi.org/10.1186/s12968-017-0387-x

6. Yoldaş T, Örün UA (2019) What is the significance of elevated troponin I in children and adolescents? A diagnostic approach. Pediatr Cardiol 40:1638–1644. https://doi.org/10.1007/s00246-019-02198-w
7. Di Bella G, Coglitore S, Zimbalatti C, Minutoli F, Zito C, Patane' S, Carerj S, (2008) Strain Doppler echocardiography can identify longitudinal myocardial dysfunction derived from edema in acute myocarditis. Int J Cardiol 126(2):279–280. https://doi.org/10.1016/j.ijcard.2007.01.110
8. Thuny F, Avierinos JF, Jop B, Tafanelli L, Renard S, Riberi A, Métras D, Habib G (2006) Massive biventricular thrombosis as a consequence of myocarditis: findings from 2-dimensional and real-time 3-dimensional echocardiography. Circulation 113(25):e932–e933. https://doi.org/10.1161/CIRCULATIONAHA.105.599167
9. Jeserich M, Konstantinides S, Pavlik G, Bode C, Geibel A (2009) Non-invasive imaging in the diagnosis of acute viral myocarditis. Clin Res Cardiol 98:753–763. https://doi.org/10.1007/s00392-009-0069-2
10. Mendes LA, Picard MH, Dec GW, Hartz VL, Palacios IF, Davidoff R (1999) Ventricular remodeling in active myocarditis. Am Heart J 138:303–308. https://doi.org/10.1016/S0002-8703(99)70116-X
11. Khanna S, Bhat A, Chen HH, Tan JWA, Gan GCH, Tan TC (2020) Left ventricular sphericity index is a reproducible bedside echocardiographic measure of geometric change between acute phase Takotsubo's syndrome and acute anterior myocardial infarction. IJC Hear Vasc 29:100547. https://doi.org/10.1016/j.ijcha.2020.100547
12. Raffaello WM, Henrina J, Huang I, Lim MA, Suciadi LP, Siswanto BB, Pranata R (2021) Clinical characteristics of de novo heart failure and acute decompensated chronic heart failure: are they distinctive phenotypes that contribute to different outcomes? Card Fail Rev 7:e02. https://doi.org/10.15420/cfr.2020.20
13. Agha HM, AbdelMassih AF, AbdelRahman MY, Milanesi O, Castaldi B, Geranio G, Putti MC, Kharabish A, Esmail R, El-Kamah G, Hamdy M, El-Baz H, Behairy N, Hanna C, El-Tagy H, Mishriky MA, Mamdouh M, Antonazzo L, Ramadan T (2018) Can myocardial remodeling be a useful surrogate predictor of myocardial iron load? A 3D echocardiographic multicentric study. Pediatr Blood Cancer 65:1–5. https://doi.org/10.1002/pbc.27272
14. Canter CE, Simpson KP (2014) Diagnosis and treatment of myocarditis in children in the current era. Circulation 129:115–128. https://doi.org/10.1161/CIRCULATIONAHA.113.001372
15. Caforio ALP, Pankuweit S, Arbustini E, Basso C, Gimeno-Blanes J, Felix SB, Fu M, Heliö T, Heymans S, Jahns R, Klingel K, Linhart A, Maisch B, McKenna W, Mogensen J, Pinto YM, Ristic A, Schultheiss H-P, Seggewiss H, Tavazzi L, Thiene G, Yilmaz A, Charron P, Elliott PM, European Society of Cardiology Working Group on Myocardial and Pericardial Diseases (2013) Current state of knowledge on aetiology, diagnosis, management, and therapy of myocarditis: a position statement of the European Society of Cardiology Working Group on Myocardial and Pericardial Diseases. Eur Heart J 34:2636–48, 2648a-2648d.https://doi.org/10.1093/eurheartj/eht210
16. Uziębło-Życzkowska B, Mielniczuk M, Ryczek R, Krzesiński P (2020) Myocarditis successfully diagnosed and controlled with speckle tracking echocardiography. Cardiovasc Ultrasound 18:19. https://doi.org/10.1186/s12947-020-00203-4

Publisher's Note